

The Corset Body Lift

®

Operative Step-by-Step Procedure
by

Alexander P. Moya, M.D.
Lewisburg, PA

For more information visit:
www.thecorsetbodylift.com

About the Author

“Over the past several years, I have discovered that **The Corset Body Lift** provides great versatility in treating a wide range of weight loss patients, from the ideal to the more complex patient with multiple skin rolls. It has allowed me to address specific areas of skin redundancy (such as the abdomen only, or to include the upper and/or lower back) as well as help those that are financially restricted, since I can limit the length and/or adjust the position of one or both transverse incisions. This overall flexibility of the procedure has significantly expanded my weight loss body contouring practice, since it can be successfully utilized (as opposed to a circumferential belt lipectomy) in a far greater number of patients, even those with significant abdominal scars (midline, paramedian or subcostal) or who are higher on the BMI scale. Regardless of the modification, the final result of **The Corset Body Lift** achieves its pre-operative goals, resulting in satisfied patients who may be eager to undergo further contouring surgery or happily refer family and friends.”

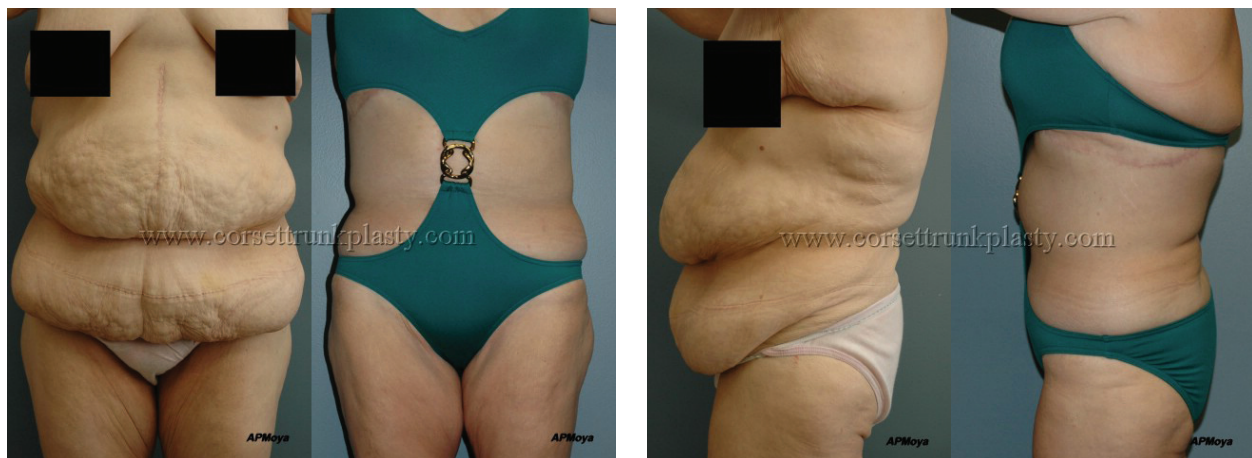Alexander P. Moya, M.D.

Board-Certified Plastic Surgeon

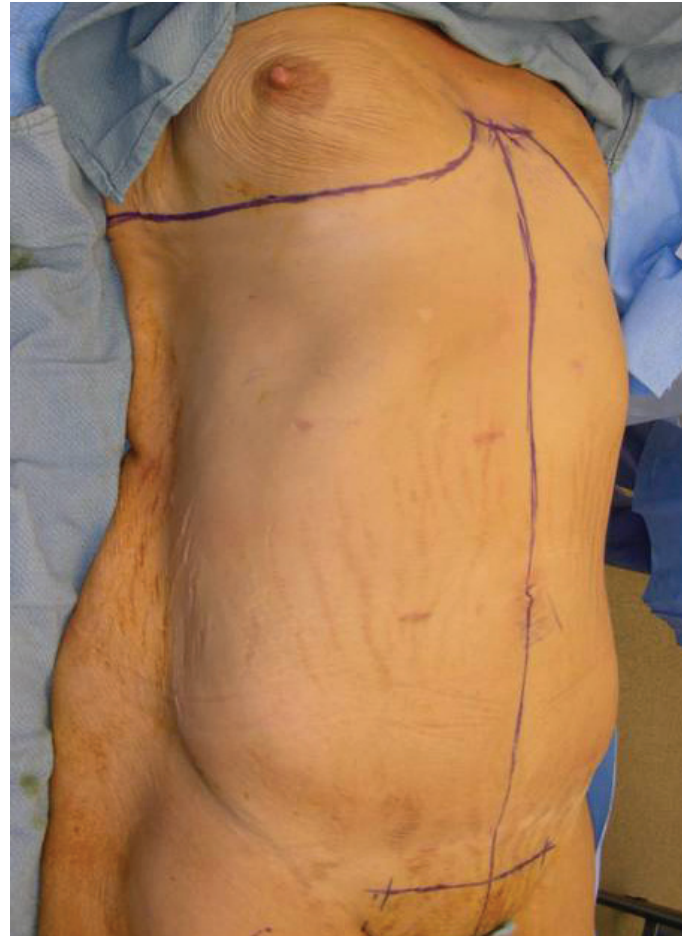
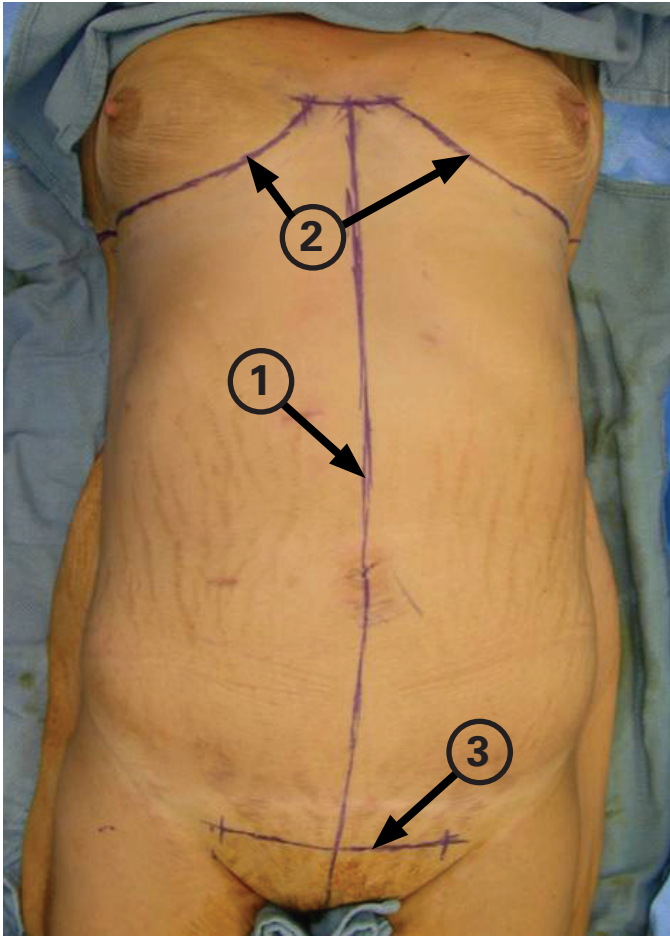


Introduction

The Corset Body Lift is an alternative approach to MWL body contouring which can be successfully utilized in a large number of patients. The procedure incorporates incisions derived from the fleur-de-lis and reverse abdominoplasties and is performed in the supine position only (without the need for repositioning). It not only directly resects redundant skin along the anterolateral trunk, but its primary closures also indirectly affect the posterior waistline, thereby resulting in a 360-degree improvement. The procedure comprehensively addresses the contour of the abdominal and waistline regions in a single-stage, with particular attention to creating an hourglass figure in women. The standardized approach to **The Corset Body Lift** is reliable, easily reproduced, does not require a post-operative drain, and is associated with a low incidence of major wound complications due to the complete lack of undermining skin for closure.



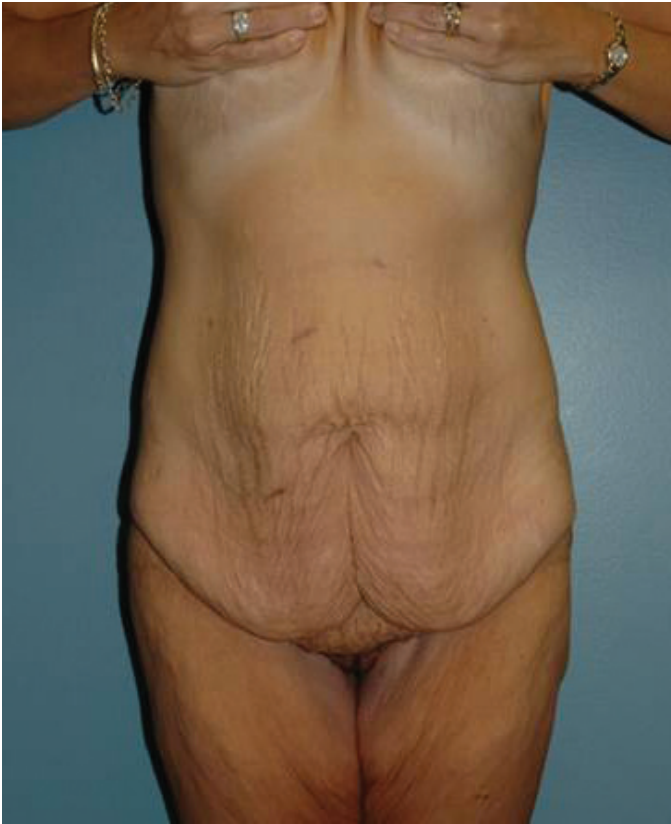*"It's not about the outside, it's about what it does on the inside.
The boost in self-esteem outweighs any external scar."*



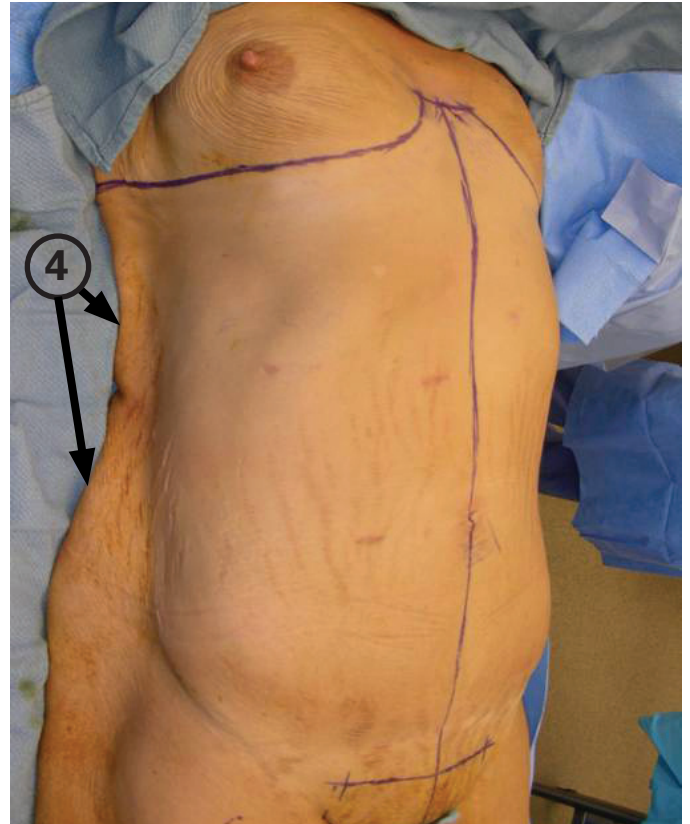Pre-operative Reference Lines

*All pre-operative markings (reference lines & vertical resection) are performed in the supine position after prepping skin from the sternal notch down to upper thighs and from side-to-side, which includes part of the back.

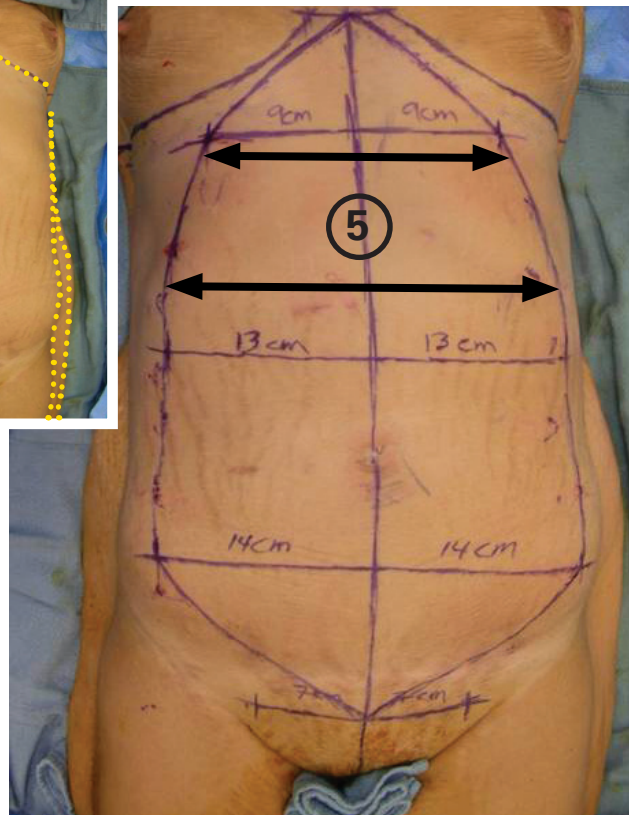
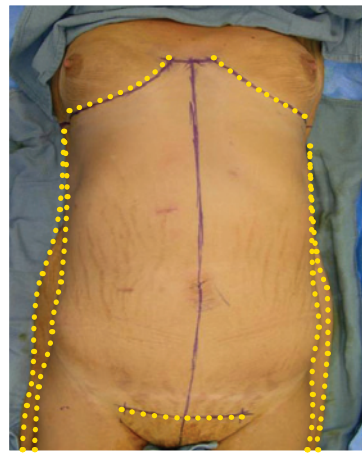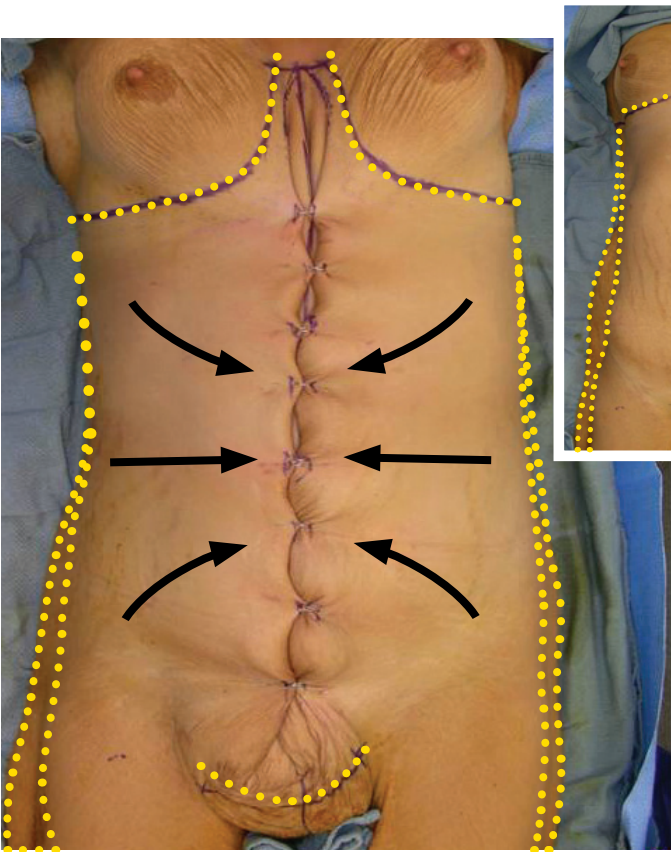
- Pre-operative reference lines consist of the vertical midline (1), lower chest (2), and pubic (3) reference lines.
- The vertical midline reference line extends from the xyphoid down to the pubis.
- The lower chest reference line extends from side-to-side and follows the IM folds in women. Its medial portions are transverse and equal in length from the midline. Its lateral portions can be variable in placement, but their final positions are chosen for maximal upper waistline contouring. The lateral portions may extend onto the upper back, following the bra line, for enhanced contouring.
- The pubic reference line is transverse and placed within the upper portion of the pubis. It is equal in length from the midline and usually ranges 16-18 cm long.



Standing position



Supine position

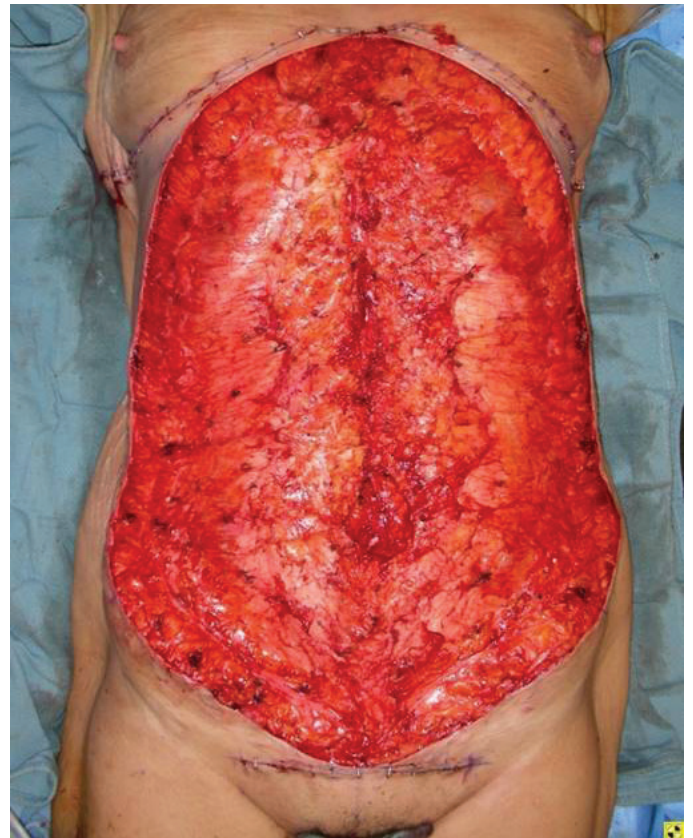
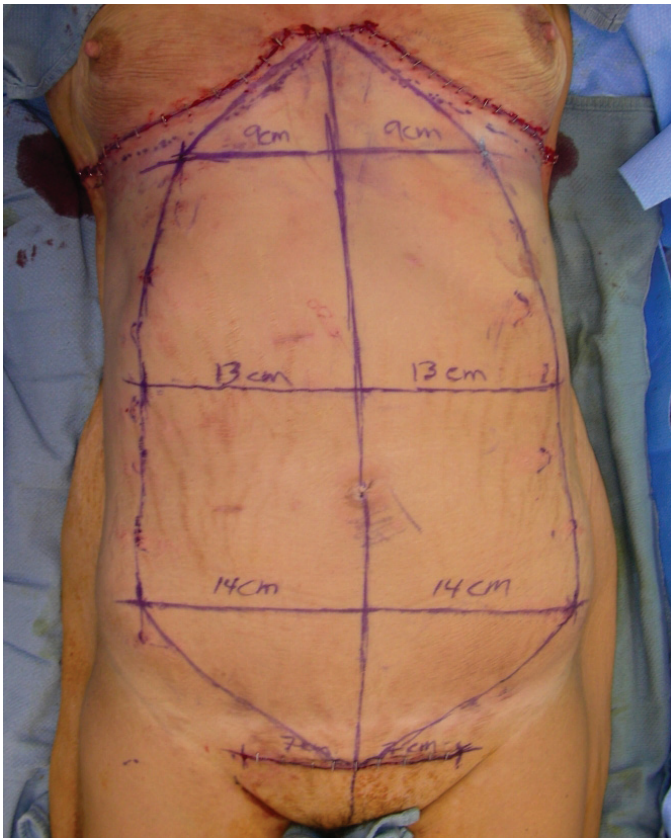


Vertical Resection Markings

*You get a much better appreciation of the degree of redundant mid-trunk (lower chest / upper abdomen) skin (4) as it drapes onto the OR table in the supine position as opposed to standing. This excess is reflected by the considerable size of the upper portion (5) of the vertical ellipse.

*The vertical resection is determined in a very standardized manner, which maximizes skin removal while guaranteeing closure of the defect without undermining.

- The horizontal skin redundancy, extending from the lower chest to flanks, is pulled to the midline, inverted and temporarily stapled. Maximal pull of the lateral skin can be employed, since the rolled up tissue to be excised allows for a margin of safety regarding final closure.
- The stapled skin is marked and released.
- Several transverse “hash lines” are drawn to aid in closure.
- The lateral skin marks (stapled areas) are adjusted along the “hash lines” to keep them equidistant from the midline in order to achieve a straight vertical scar.
- A large vertical ellipse is outlined by connecting the midpoint of the lower chest reference line, the lateral skin marks on both sides and the midpoint of the pubic reference line.

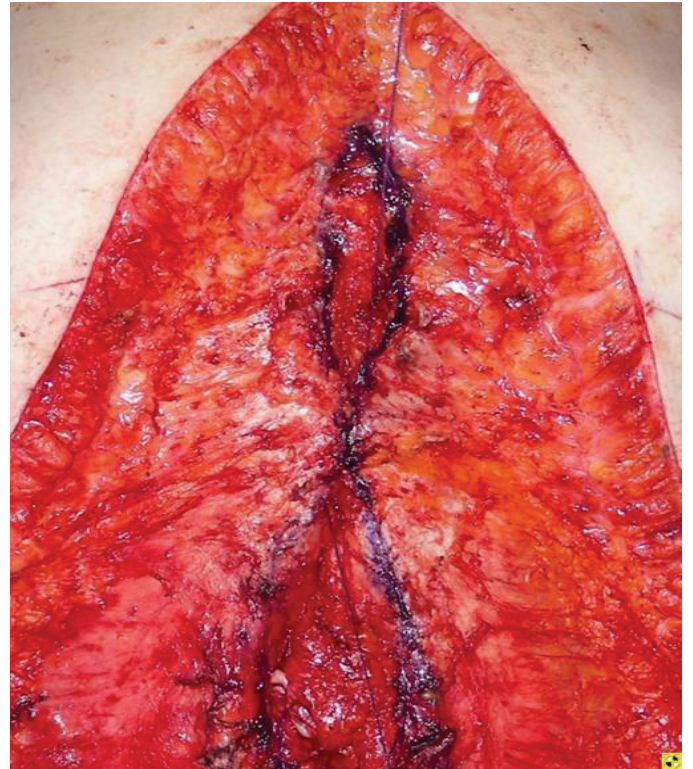
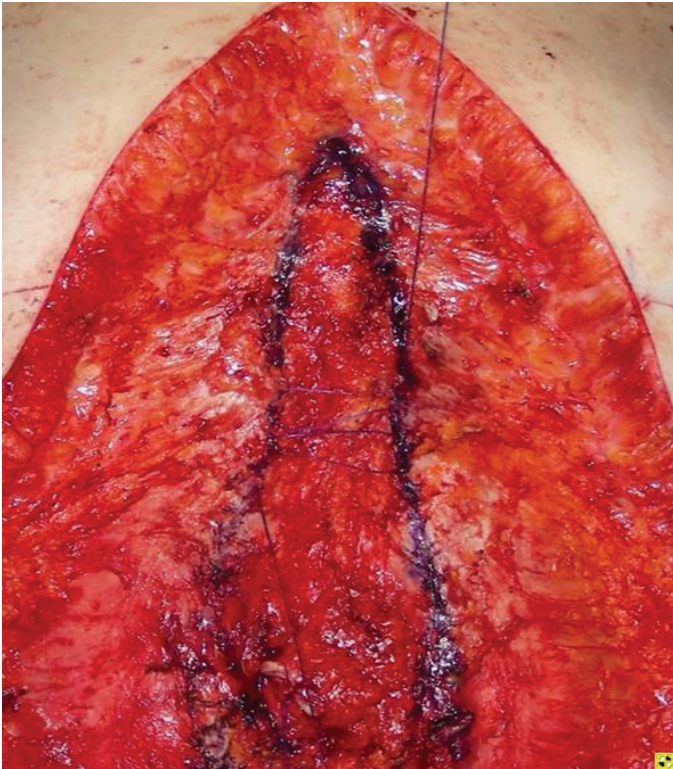
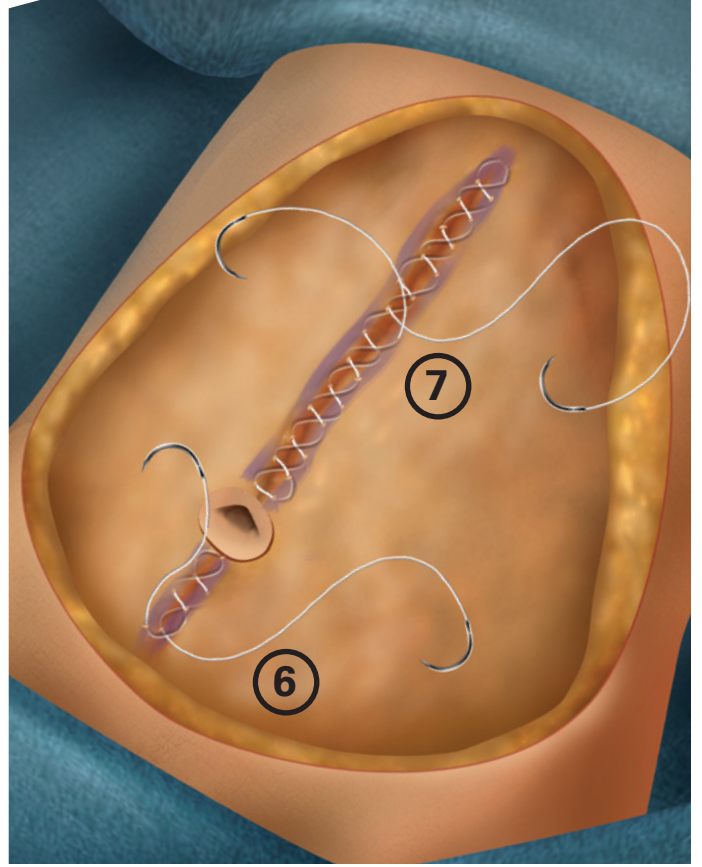
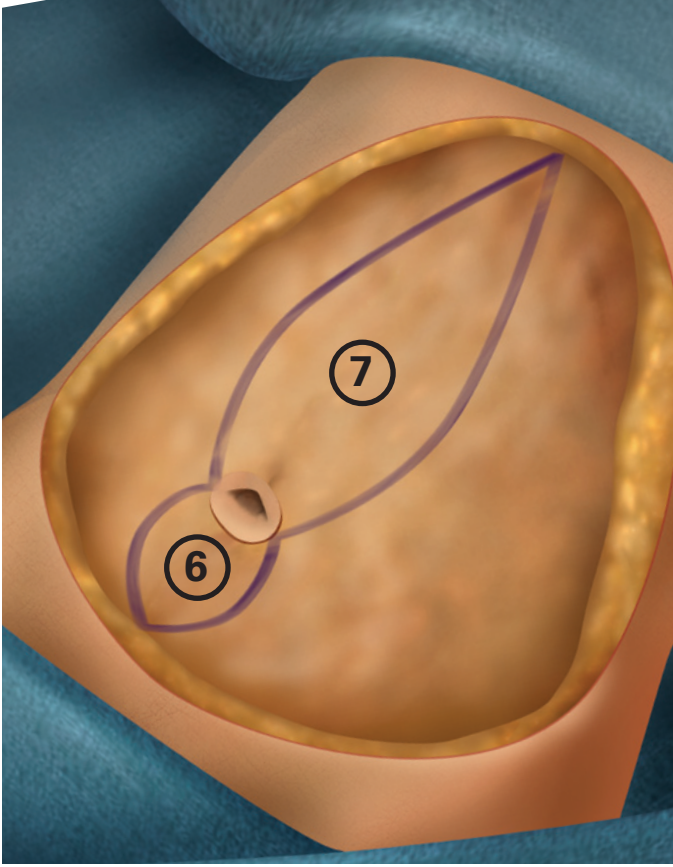


Vertical Resection Technique

*HARMONIC® (ultrasonic) Technology, blade and shear instruments, if used as the exclusive working energy source for the procedure, is the greatest contributor to a drain-free recovery. Blade use is performed with a wetting solution (standard liposuction fluid) as compared to a shear. This solution appears to reduce the amount of small “bleeders” and increases the efficiency of the instrument. Blade use requires a fair amount of surrounding tissue tension and direct contact with ample pressure on the tissues being cut. Shear use employs a “clamp and turn” dissection technique, which seals all vessels within its jaws, leaving the surgical field less bloody. The use of HARMONIC® devices is described throughout the technique.

*The vertical resection can encompass part of the lower chest and the entire abdominal skin.

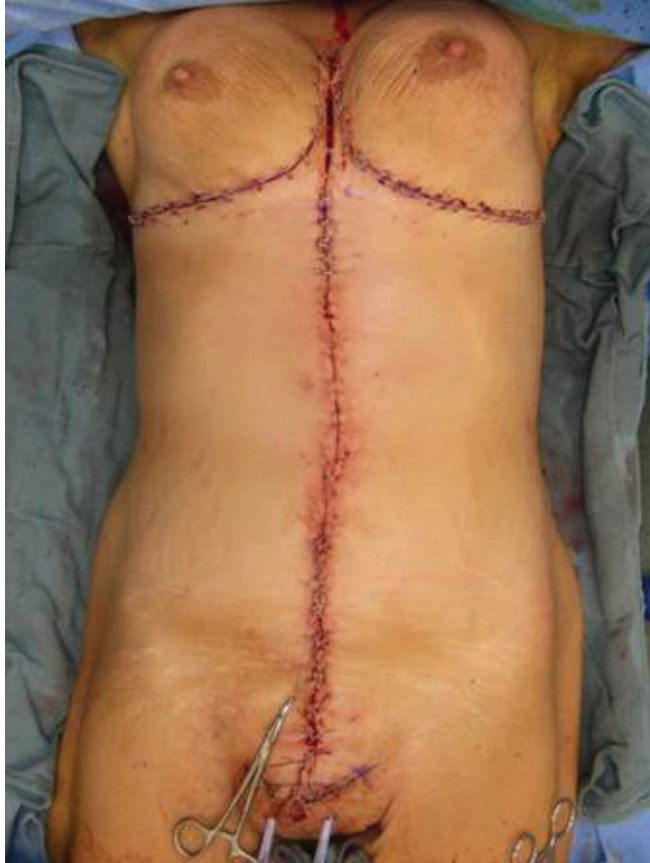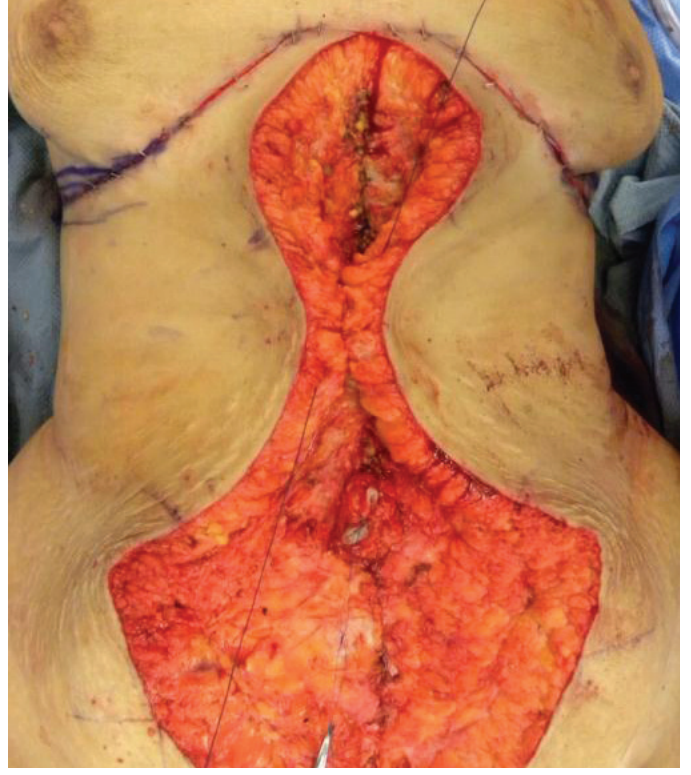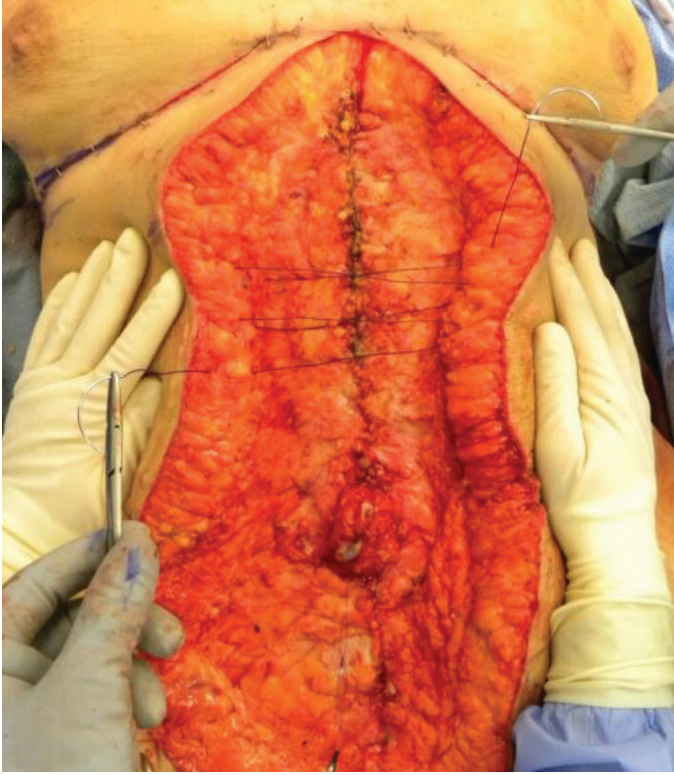
- The subcutaneous tissues along the proposed incision sites are infiltrated with a wetting solution for use of the HARMONIC® Combination Hook Blade.
- The “hash lines” along the vertical ellipse and the ends of the transverse portions of the lower chest and pubic reference lines are scored.
- The lower chest and pubic reference lines are incised with a scalpel and immediately reapproximated with a skin stapler. This maneuver preserves the markings for future resections (lower chest and lower trunk).
- The umbilicus is released from the skin.
- The vertical ellipse is incised with a scalpel and dissection is carried straight down to the abdominal and chest wall with the HARMONIC® Combination Hook Blade.
- The vertical ellipse is resected off the abdominal and chest wall with the Harmonic Focus® Curved Shears.



Abdominal Wall Plication

*Abdominal wall plication can be easily performed due to the extent of exposure. This step not only enhances overall abdominal contour but reduces the size of the defect, facilitating closure by pulling the lateral skin edges together without undermining.

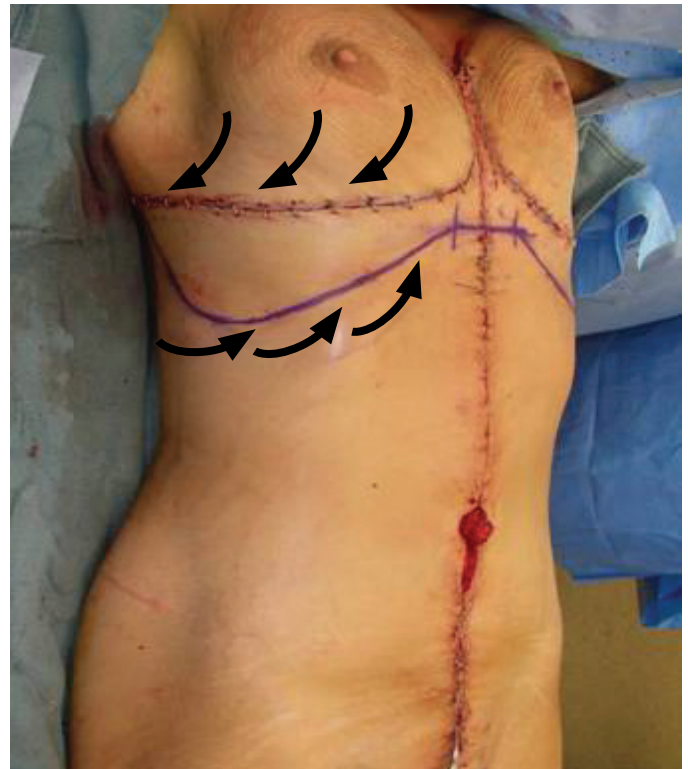
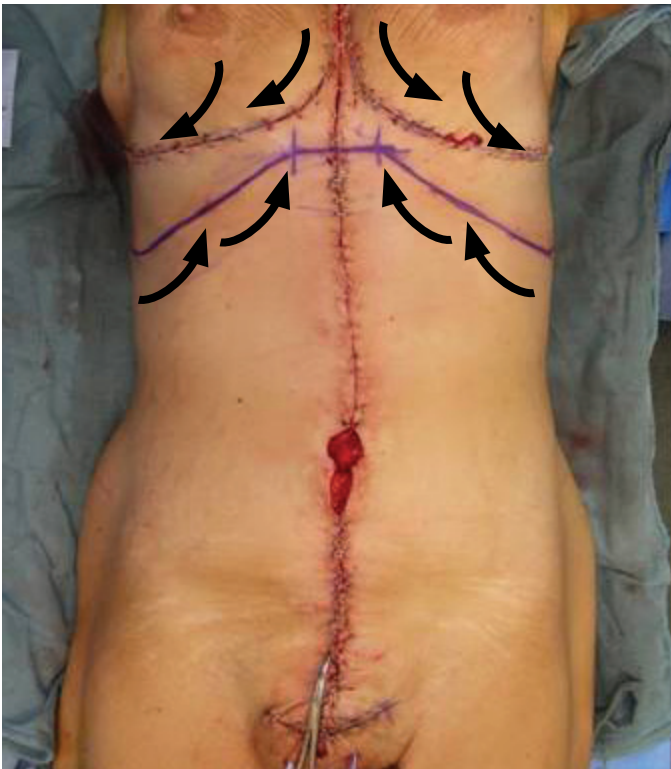
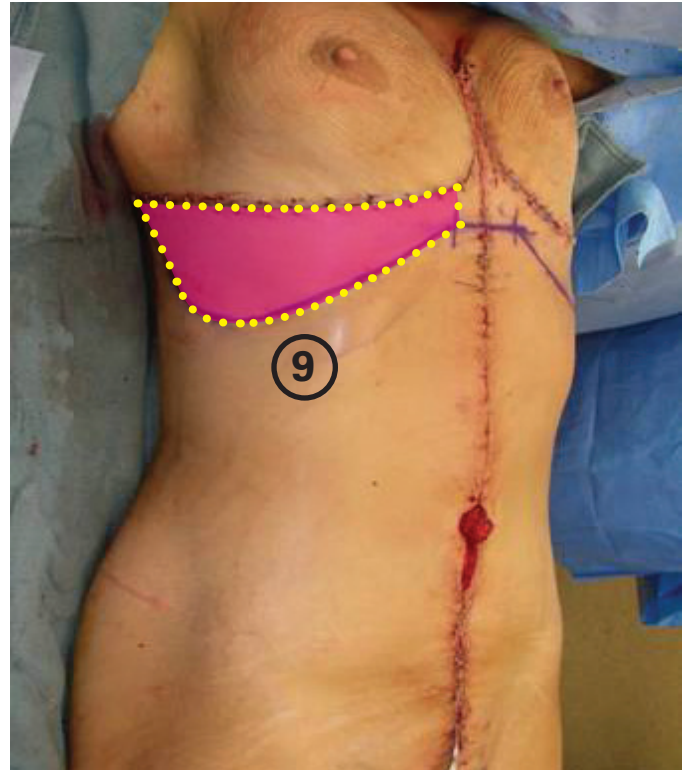
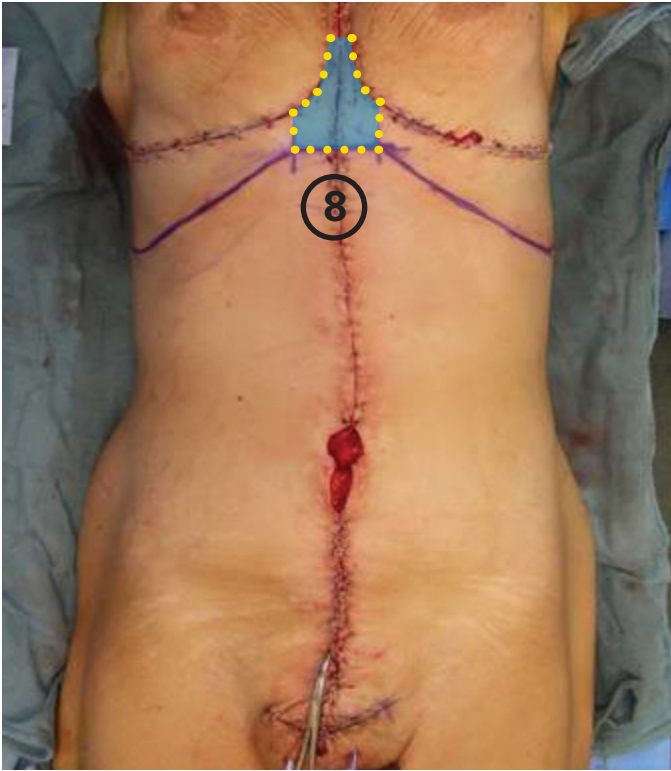
- #2 Quill™ PDO or PPN devices with bidirectional barbs are utilized for plication. The choice of suture depends on the body frame size. PPN is preferred for larger abdominal girths. Each Quill™ device provides a two-layered plication (vertical stitches). One suture is used for the lower abdominal wall (umbilicus down to pubic symphysis) (6) and a second suture is used for the upper abdominal wall (xyphoid down to umbilicus) (7). Each suture needs to terminate one-half the distance around the umbilicus in order to maximize the effect of the plication (avoiding laxity around the umbilicus and the necessity for additional sutures).



Vertical Closure

* The proper use (based upon selection of material and suturing technique) of Quill™ device reduces the overall operative time and provides a secure and reliable closure.

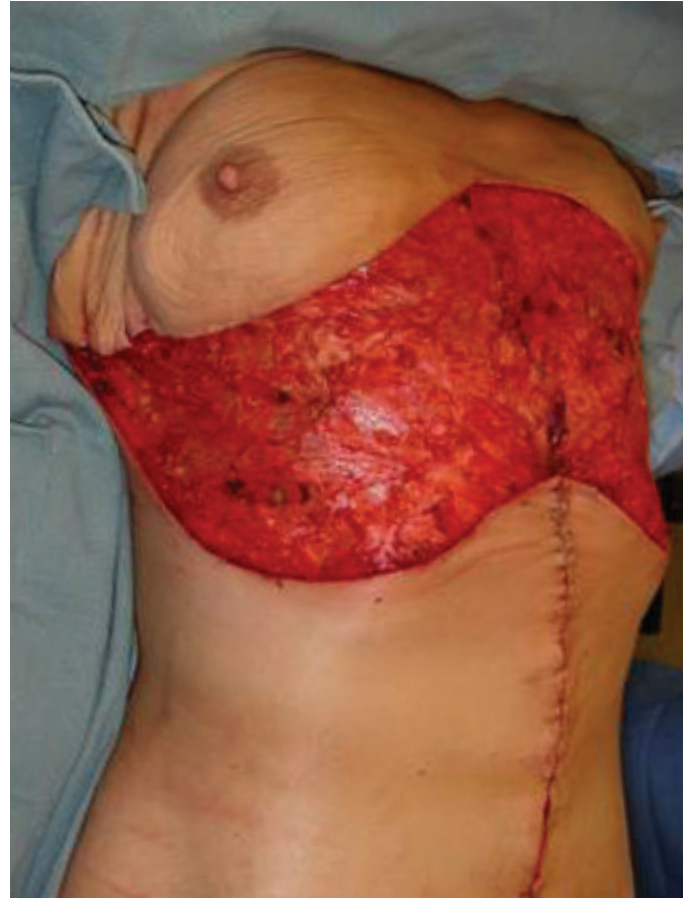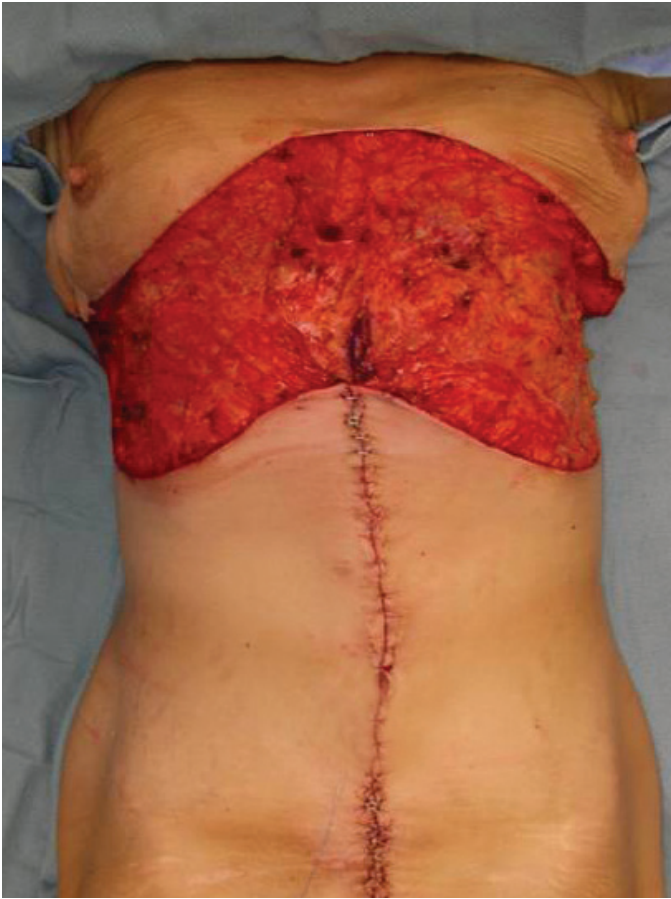- The upper abdominal superficial fascia is reapproximated with a #2 Quill™ PDO device. A large-gauge suture is preferred for added strength regardless of patient size (no issue in thin patients since there are no knots). Single-layer bidirectional suture placement starts along the midpoint of the xyphoid and umbilicus. After several throws are placed in opposite directions, the barbs are locked into the tissues while an assistant pushing the skin edges together reduces the tension along the closure (avoiding potential suture rupture). The suture ends are pulled parallel to the wound using the suture material itself, avoiding potential suture rupture and accidental needle pop-off, respectfully. Superficial fascia is repaired moving toward the xyphoid, stopping just prior to where the upper midline “dog ear” will be resected. Superficial fascia is then repaired moving toward the umbilicus, stopping just prior to where it will be inset along the vertical incision.
- The skin over the repaired upper abdominal fascia is temporarily reapproximated with staples.
- The wound below the umbilicus (lower abdomen) is temporarily closed with skin staples only.



Lower Chest Resection Markings

*The goals of the lower chest resection are to remove the upper midline “dog ear” (8) created by the vertical closure and to remove the redundant lateral chest skin (9) (may also be extended to include redundant upper back skin). The “dog ear” can be the only portion addressed, as needed (due to body habitus or patient financial constraints), depending on the expected outcome (modified corset trunkplasty).

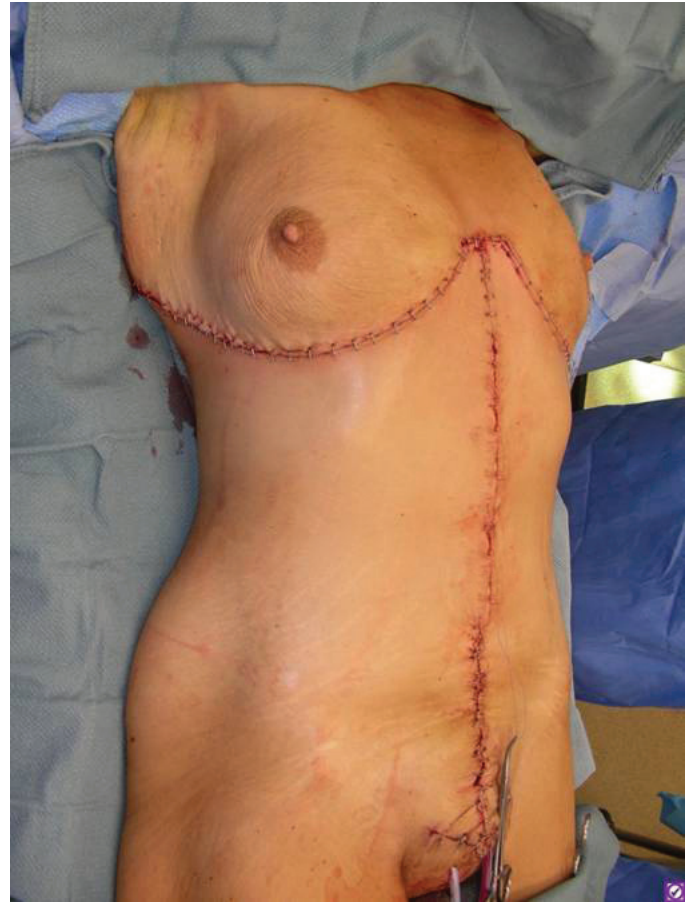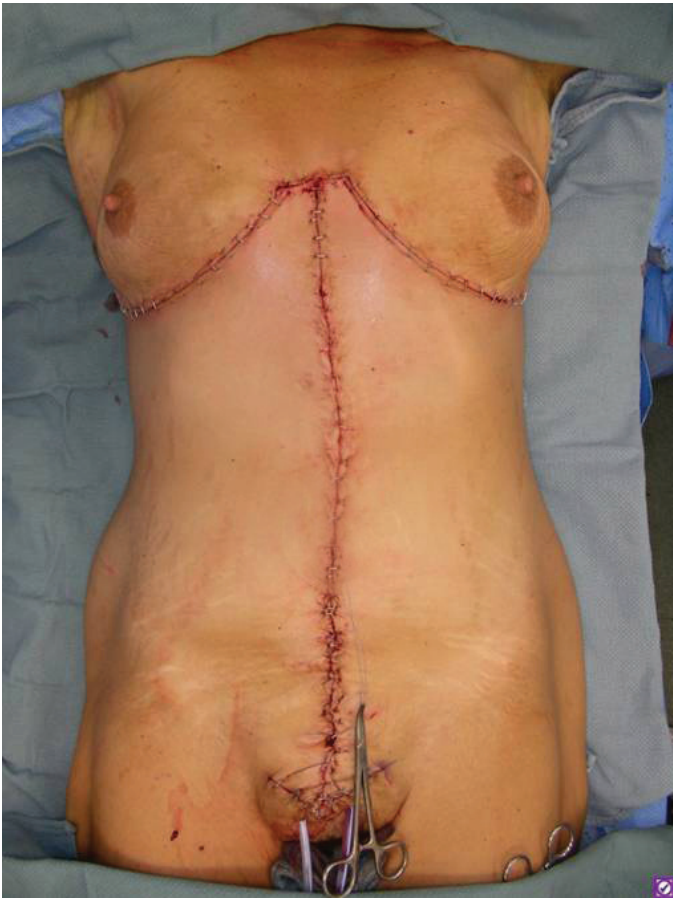- A tailor-tacking technique is used to identify the inferior resection margins along the abdominal flaps for the removal of the upper midline “dog ear”. The overall transverse length is made to match the corresponding portion of the lower chest reference line.
- A tailor-tacking technique is used to mark the excess lateral chest skin (may be extended onto the upper back). The markings are determined by pulling the inferior tissue up to the lower chest reference line and serve as a guide for outlining the lower chest resection on both sides.
- The final resection outline incorporates the recreation (tissues sliding into place) of the IM folds.



Lower Chest Resection Technique

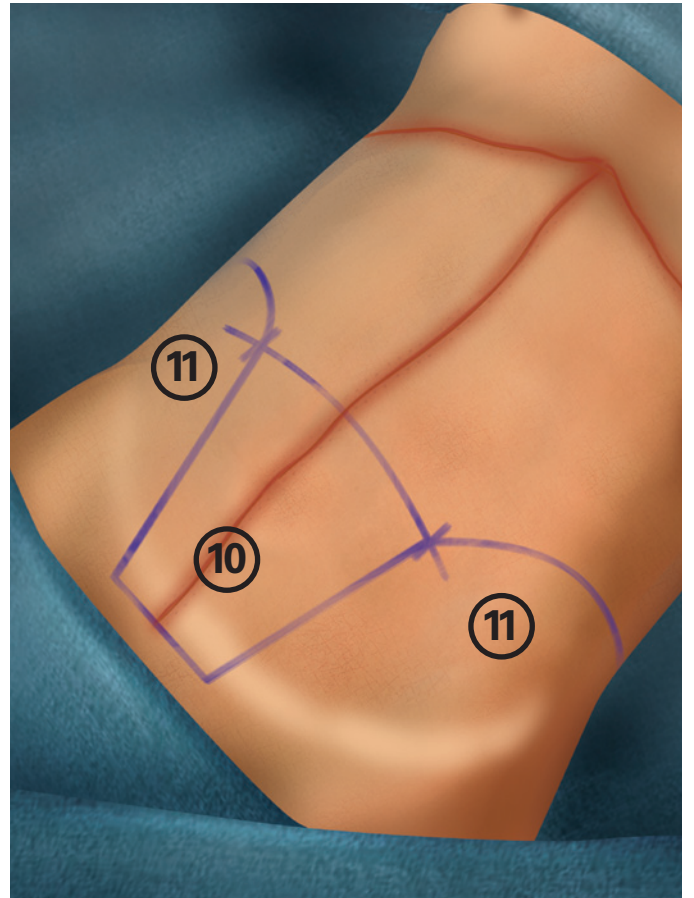
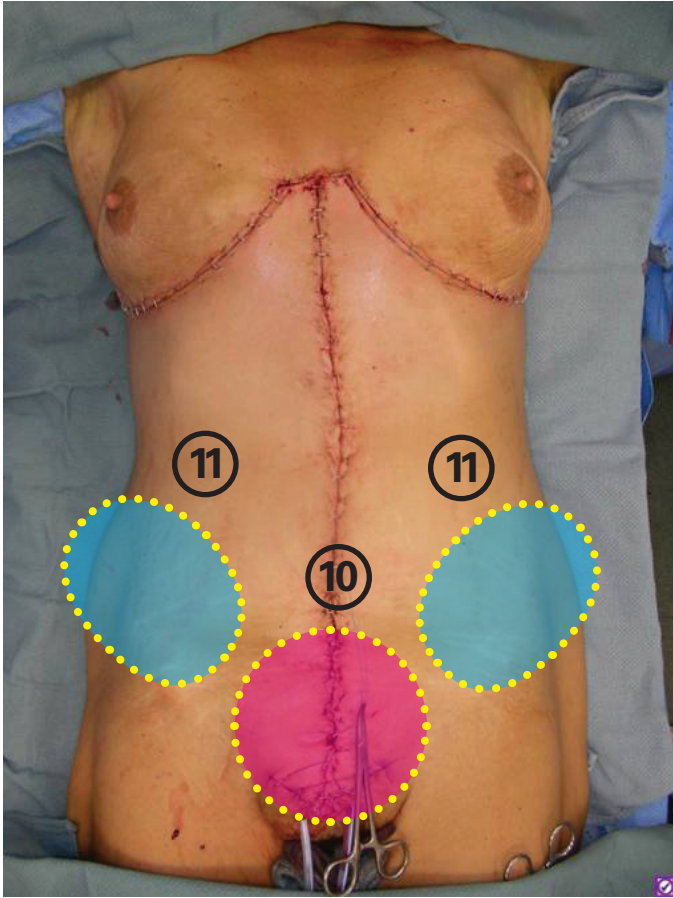
*The lower chest resection can extend from one scapula to the other depending on the amount of redundant lateral chest skin.

- The subcutaneous tissues along the proposed incision sites are infiltrated with a wetting solution for use of the HARMONIC® Combination Hook Blade.
- All skin markings are incised with a scalpel.
- Dissection (using HARMONIC® Combination Hook Blade) down to the chest wall along the lower chest reference line is performed in a perpendicular fashion to the skin. This aids in correctly identifying the position of the IM folds during closure.
- Dissection (using HARMONIC® Combination Hook Blade) down to the chest wall along the inferior resection margins is performed in an oblique fashion to the skin (away from the upper abdominal flap edges). This aids in preserving the vascularity of the skin corners, since the origin of its blood supply is higher than the incision and may be compromised by a perpendicular approach.
- The redundant lower chest skin is resected off the chest wall using Harmonic Focus® Curved Shears.



Lower Chest Closure

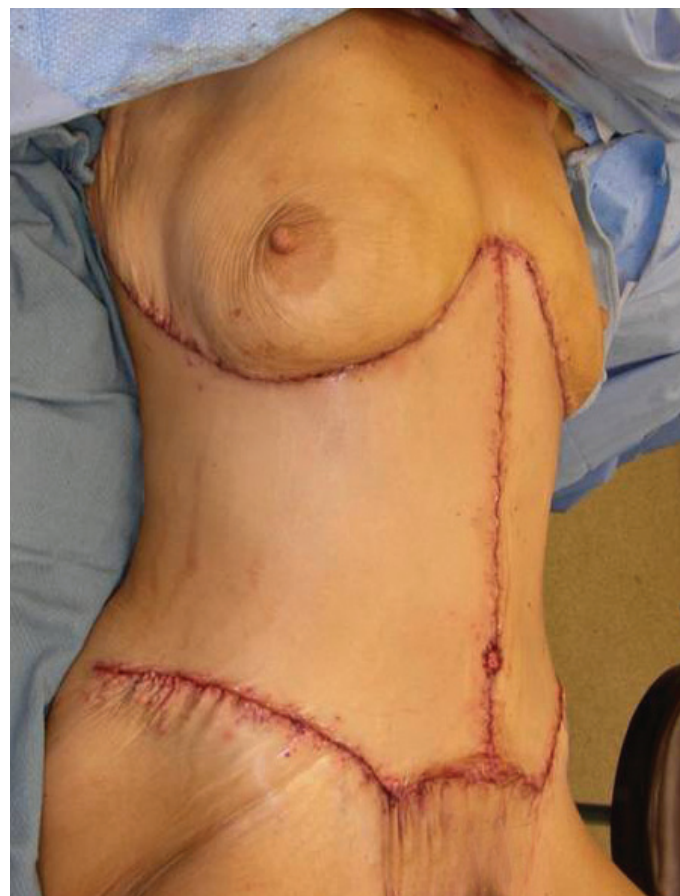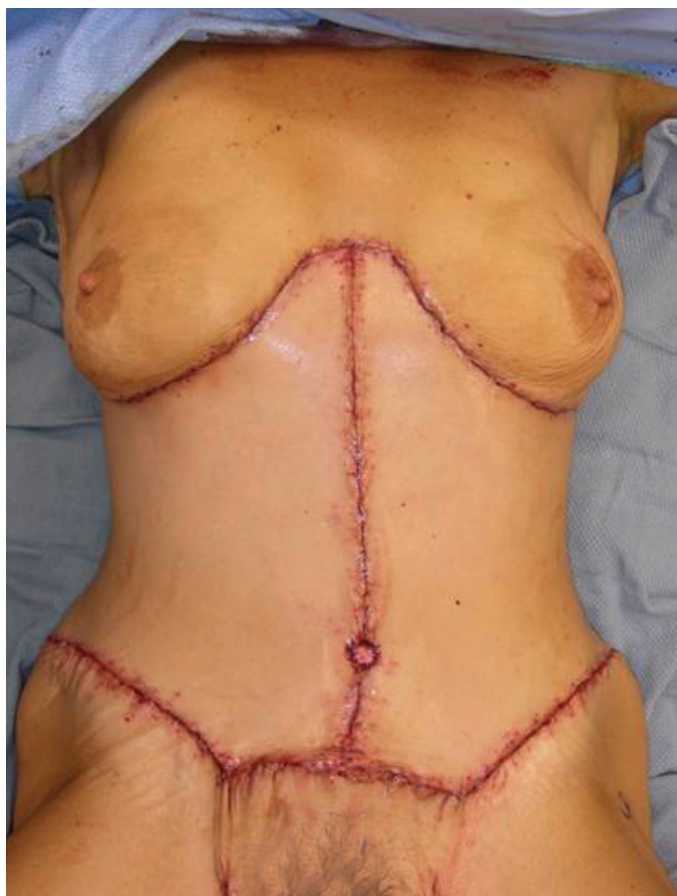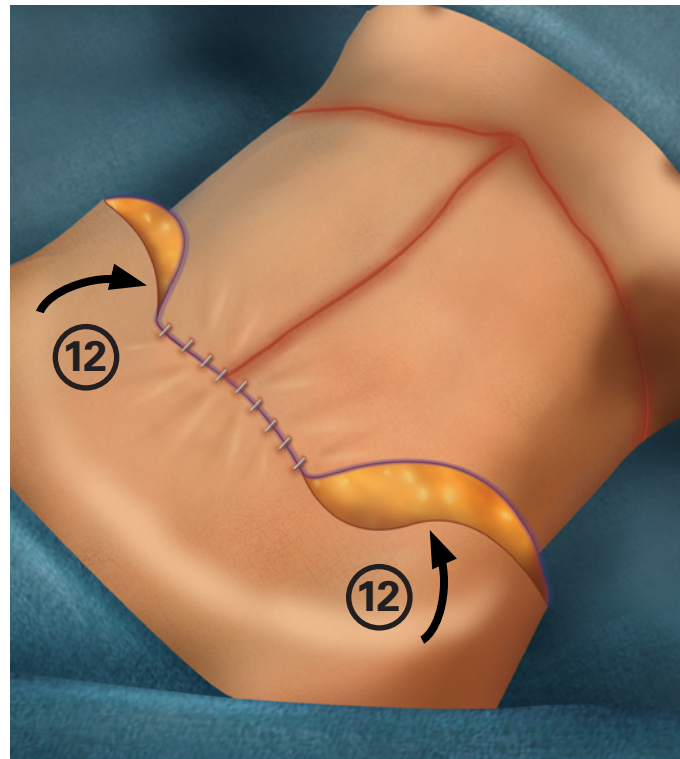
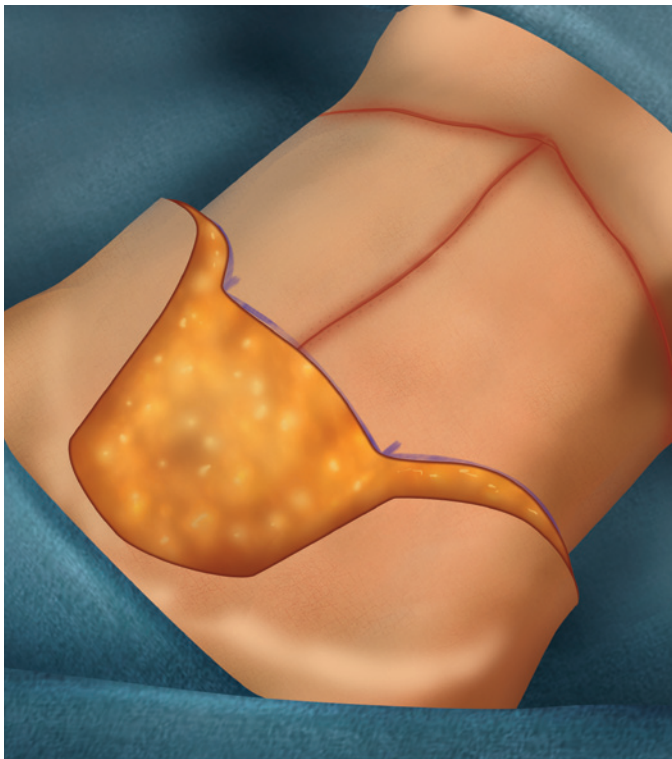
- The superficial fascia of the medial (abdominal skin corners) and lateral ends of the upper transverse incision are tacked down to the chest wall with #1 PDS™. These stitches are placed along the previously dissected lower chest reference line for proper flap positioning (aids in stabilizing the scar at the IM fold).
- Dermis along the upper abdominal flap skin corners is reapproximated to the midpoint of the lower chest reference line with a 3-0 Monocryl™ suture.
- The lateral chest wounds are repaired with the same suture (#2 Quill™ PDO device) and suturing technique as the vertical closure. The abdominal flaps are again secured to the chest wall along the previously dissected lower chest reference line (aids in stabilizing the scar at the IM fold).
- The superficial fascia closure of the upper vertical midline is completed.
- Skin is temporarily reapproximated with staples.



Lower Trunk Resection Markings

*The goals of the lower trunk resection are to remove the lower midline “dog ear” (10) created by the vertical closure and to remove the redundant lower waistline skin (flank, hip, and even lower back) (11). Again, the “dog ear” can be the only portion addressed, as needed (due to body habitus or patient financial constraints), depending on the expected outcome (modified corset trunkplasty).

- The patient is flexed to maximize removal of lower trunk skin.
- A tailor-tacking technique is used to identify the lower transverse markings along the abdominal flaps. Its overall transverse length is made to match the pubic reference line. Connecting the ends of the lower transverse markings and the pubic reference line outlines the central vertical redundancy (lower midline “dog ear”).
- The lower waistline is addressed by marking the position of the lateral incisions. They may be placed low on the hips and length kept short to complete the lower midline “dog ear” resection only (markings completed in one-stage). They may be placed high on the hips to enhance the abdominal-to-hip contour and overall lengths adjusted as needed (standard length for anterior hip contour only or extended length to also address lower back skin rolls and posterior waistline contour). Only the superior markings are outlined unless the lower midline “dog ear” is only being resected (inferior markings to be completed during the resection via a flap-splitting approach). The lateral markings are kept symmetric to one another as opposed to matching their positions on the body.



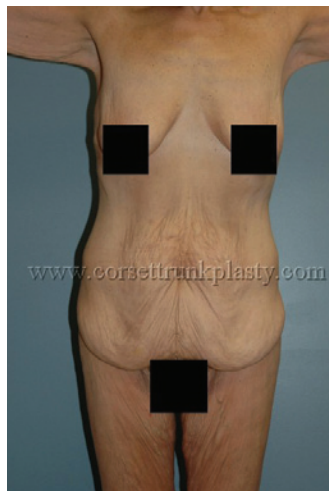Lower Trunk Resection Technique & Closure

*The lower trunk resection can extend onto the lower back depending on the amount of redundant skin to be removed.

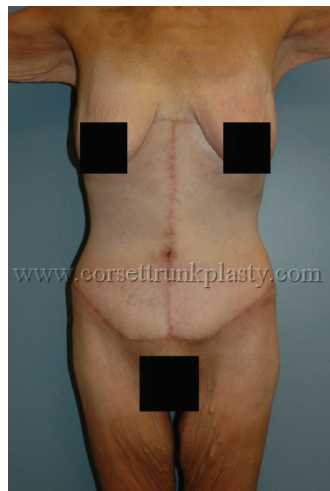*The final on-table shape appears to be that provided by a corset.

- The subcutaneous tissues along the proposed incision sites are infiltrated with a wetting solution for use of the HARMONIC® Combination Hook Blade.
- All skin markings are incised with a scalpel.
- Dissection (using HARMONIC® Combination Hook Blade) down to the abdominal wall along the superior resection margins is performed in an oblique fashion to the skin (away from the lower abdominal flap edges). This aids in preserving the vascularity of the skin corners, since the origin of its blood supply is lower than the incision and may be compromised by a perpendicular approach.
- The redundant lower trunk skin is resected off the abdominal wall, hips, and lower back with the Harmonic Focus® Curved Shears.
- Superficial fascia along the medial (abdominal skin corners) and lateral ends of the lower transverse incision are reapproximated to the pubic reference line with #1 PDS™.
- Dermis of the lower abdominal flap skin corners are reapproximated to the midpoint of the pubic reference line with 3-0 Monocryl™ suture.
- The lower transverse wound is temporarily closed with skin staples.
- Inferiorly based random pattern skin flaps (12) are elevated off the hips (and lower back as needed) if more than the lower midline “dog ear” is being addressed. They are advanced superomedially to avoid a “dog ear” and the excess is marked and removed utilizing a flap-splitting technique.
- Lateral wounds are temporarily closed with skin staples, which usually require pleating to properly deal with unequal incision lengths. Hash lines are drawn across the closure to help maintain alignment during superficial fascia repair.
- All skin staples (lower transverse and lateral wounds) are replaced with a multilayered closure. Superficial fascia is repaired with #2 Quill™ PDO device and dermis is repaired with 2-0 Quill™ Monoderm™ device.
- Umbilicus is inset with 4-0 Monocryl™ suture.
- Superficial fascia repair of the vertical midline around the umbilicus is completed with #2 Quill™ PDO device. The remaining suture end from the closure of the upper vertical midline, as well as one of the suture ends from the lower lateral/lower transverse wounds can be utilized.
- All skin staples (lower chest and vertical wounds) are replaced with 2-0 Quill™ Monoderm™ device.
- All suture lines are sealed with two coats of Dermabond™ adhesive.

Before & After Photos

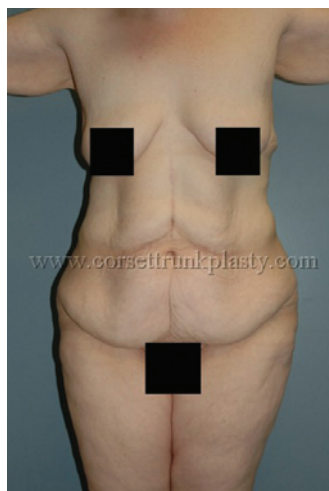

Pre-Op

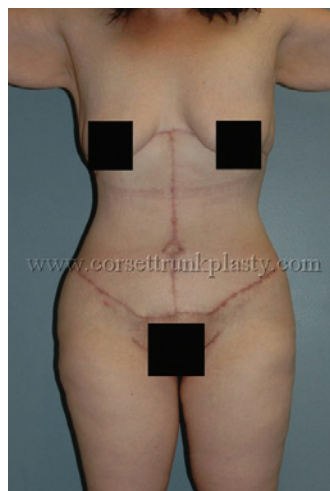

3 Months Post-Op

52 year-old WF, BMI 20, s/p laparoscopic gastric bypass with 140-lb weight loss. Corset Trunkplasty resulting in 5½-lb skin resection.

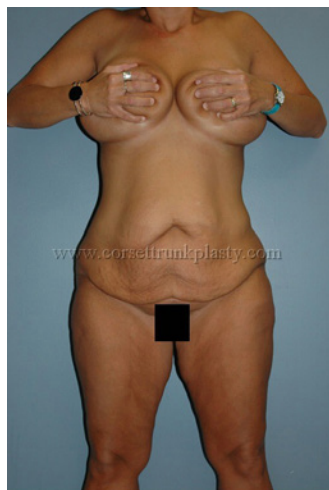

Pre-Op

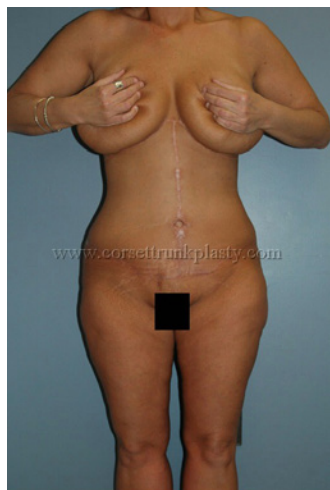

3 Months Post-Op

28 year-old WF, BMI 31, s/p open gastric bypass with 140-lb weight loss. Corset Trunkplasty (combined with medial thighplasties) resulting in 9½-lb skin resection.



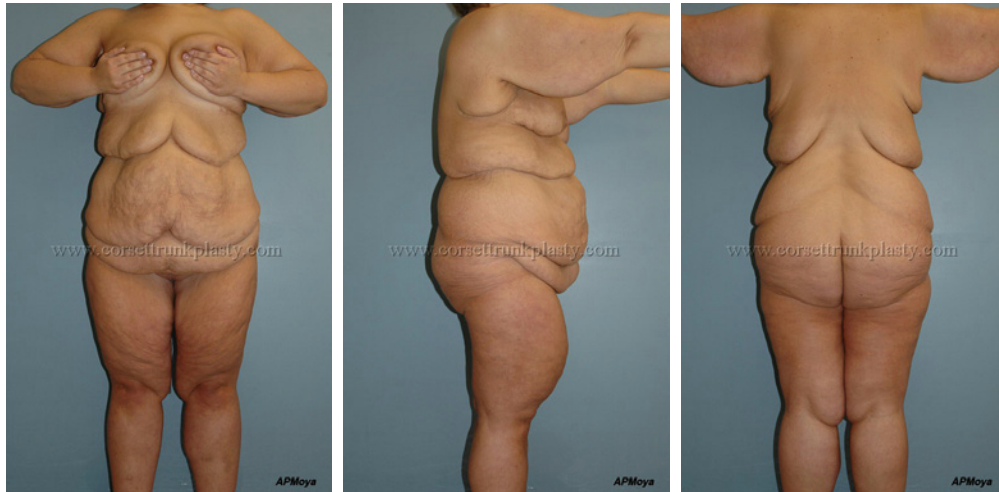Pre-Op



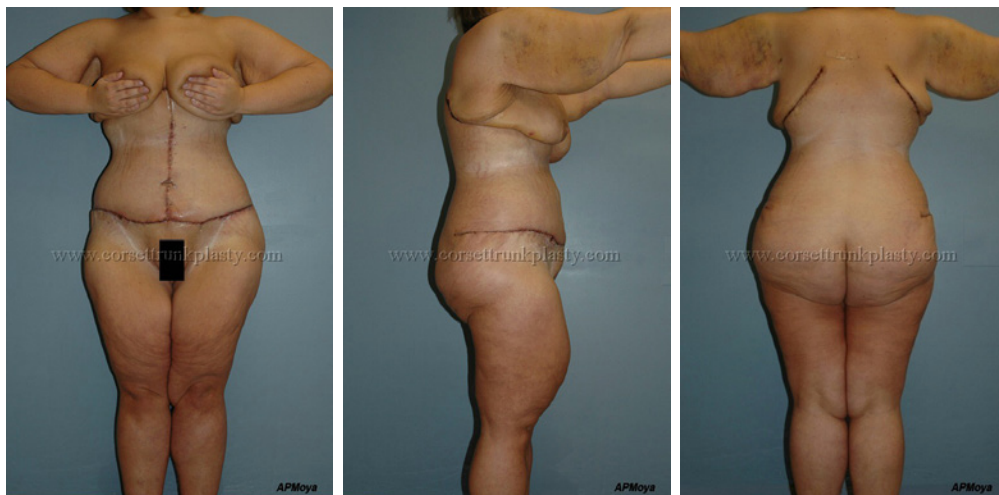6 Months Post-Op

38 year-old WF, BMI 27, s/p laparoscopic gastric bypass with 100-lb weight loss. Corset Trunkplasty (combined with medial thighplasties) resulting in 6¾-lb skin resection.

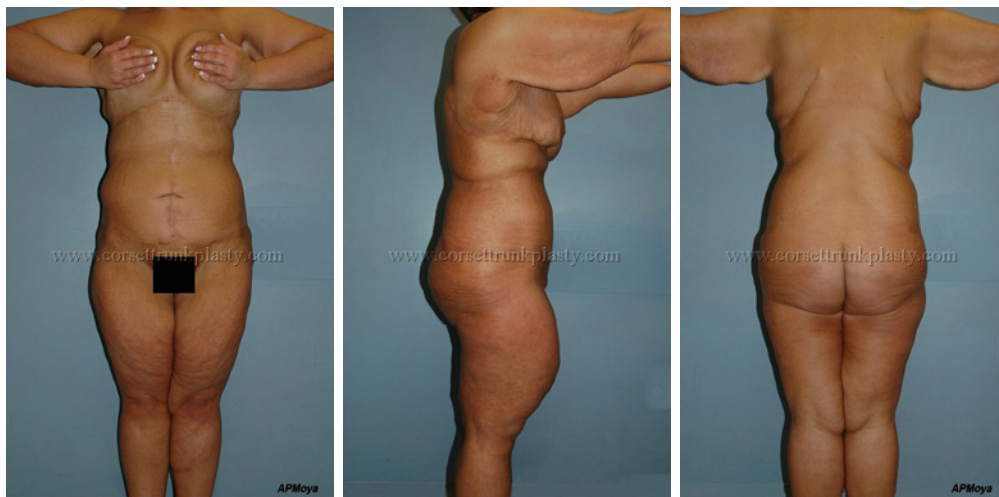28 year-old WF, BMI 37, s/p laparoscopic gastric bypass with 160-lb weight loss.
Corset Trunkplasty resulting in 20¾-lb skin resection without the use of a post-operative drain.



Pre-Op



1 Week Post-Op



1 Year Post-Op

MOYA | AESTHETICS AND PLASTIC SURGERY

www.MDMoya.com

Quill™ is a trademark of Quill Medical, Inc.

Monoderm™ is a trademark of Surgical Specialties Corporation

Monocryl™ and PDS™ are trademarks of Ethicon, Inc.

HARMONIC® Combination Hook Blade and Harmonic Focus® Curved Shears are registered trademarks of Ethicon Endo-Surgery

Dermabond™ is a trademark of Johnson & Johnson

For more information visit:
www.thecorsetbodylift.com